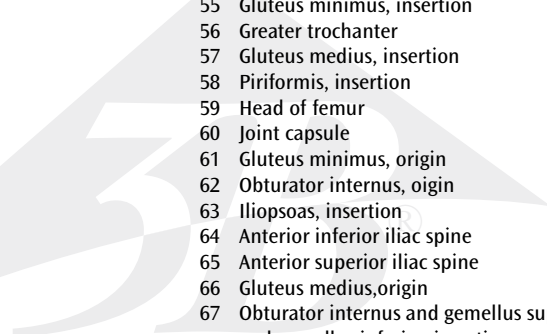


Hip joint

English

The model shows the right hip joint of a male with the individual muscles as well as the muscle origins and insertions on the femur and the hip bone. For educational purposes, the origin and insertion areas of the muscles have been raised and presented in colour (muscle origin = red; muscle insertion = blue). The hip muscles have been mounted on their corresponding regions of origin and insertion and are thus removable.

- 
- 1 Iliacus
 - 2 Quadratus lumborum, origin
 - 3 Hip bone
 - 4 Psoas major
 - 5 Superior pubic ramus
 - 6 Pectineus, origin
 - 7 Rectus abdominis, insertion
 - 8 Obliquus internus abdominis, insertion
 - 9 Adductor longus, origin
 - 10 Adductor brevis, origin
 - 11 Gracilis, origin
 - 12 Adductor magnus, origin
 - 13 Obturator externus, origin
 - 14 Inferior pubic ramus
 - 15 Iliopsoas
 - 16 Vastus intermedius, origin
 - 17 Femur
 - 18 Vastus lateralis, origin
 - 19 Gluteus minimus
 - 20 Rectus femoris, origin
 - 21 Gluteus medius
 - 22 Sartorius, origin
 - 23 Obliquus externus abdominis, insertion
 - 24 Obliquus internus abdominis, origin
 - 25 Transversus abdominis, origin
 - 26 Erector spinae, origin
 - 27 Piriformis
 - 28 Coccygeal muscle, origin
 - 29 Levator ani, origin
 - 30 Gluteus maximus
 - 31 Sacrotuberous ligament
 - 32 Obturator internus
 - 33 Superficial transverse perineal muscle, origin
 - 34 Ischiocavernosus origin
 - 35 Deep transverse perineal muscle, origin
 - 36 Vastus medialis, origin
 - 37 Latissimus dorsi, origin
 - 38 Gemellus superior
 - 39 Gemellus inferior
 - 40 Quadratus femoris
 - 41 Pectineus, insertion
 - 42 Gluteus maximus, insertion
 - 43 Adductor magnus, insertion
 - 44 Adductor brevis, insertion
 - 45 Biceps femoris, origin
 - 46 Semitendinosus, origin
 - 47 Tensor fasciae latae, origin
 - 48 Semimembranosus, origin
 - 49 Iliacus, origin
 - 50 Greater sciatic foramen
 - 51 Quadratus femoris, origin
 - 52 Sciatic tuber
 - 53 Neck of femur
 - 54 Lesser trochanter
 - 55 Gluteus minimus, insertion
 - 56 Greater trochanter
 - 57 Gluteus medius, insertion
 - 58 Piriformis, insertion
 - 59 Head of femur
 - 60 Joint capsule
 - 61 Gluteus minimus, origin
 - 62 Obturator internus, origin
 - 63 Iliopsoas, insertion
 - 64 Anterior inferior iliac spine
 - 65 Anterior superior iliac spine
 - 66 Gluteus medius, origin
 - 67 Obturator internus and gemellus superior and gemellus inferior, insertion
 - 68 Obturator externus, insertion
 - 69 Quadratus femoris, insertion
 - 70 Gemellus inferior, origin
 - 71 Ischial spine
 - 72 Gemellus superior, origin
 - 73 Gluteus maximus, origin

